



## Clinical Report on an Implant-Supported Overdenture in a Parkinson's Patient

### Autros:

Tamana Barakati <sup>1</sup>, Elaha Somaya Ghafari<sup>2</sup>, Somayeh Niakan<sup>3</sup>, Omid Humkar<sup>4</sup>, Hasina Shadab<sup>2</sup>, Hedayatullah Ehsan <sup>5</sup>

<sup>1</sup>Research Department, Queen Mary University of London, London, UK; <sup>2</sup>Department of Periodontology, Kabul University of Medical Science, Kabul, Afghanistan; <sup>3</sup>Department of Prosthodontics, Tehran University of Medical Sciences, Tehran, Iran; <sup>4</sup>Oral Medicine Department, Noman Sadat Institute of Higher Education, Kabul, Afghanistan; <sup>5</sup>Medical Sciences Research Center, Ghalib University, Kabul, Afghanistan

### Abstract:

Speaking, chewing, and swallowing difficulties can result from Parkinson's disease (PD), which frequently affects the oro-pharyngeal muscles. The reduction in food and hydration intake that is unavoidable leads to a worsening of neurological symptoms. Patients with Parkinson's disease experience significant challenges when adjusting to wearing entire dentures. Each of these problems presents a considerable challenge for the doctor in terms of prosthodontic rehabilitation. This case study describes how a patient with Parkinson's disease was able to employ flexible removable partial dentures supported by implants to replace both their full and partial set of missing teeth. A well-made prosthesis will help the patient with their psychological, functional, and aesthetic impairments.

**Keywords:** Parkinson disease, dentistry, implants, jaw relation



## Introduction

In 1817, James Parkinson laid the foundation for the understanding of Parkinson's disease (PD), a distinct movement disorder, in his essay "Essay on the Shaking Palsy." Emerging typically in the fifth or sixth decade of life, PD stands as the second most prevalent neurodegenerative disease of the central nervous system, with an incidence rate ranging from 1% to 2%. Notably, males exhibit a higher susceptibility than females.<sup>1–4</sup> While the majority of PD cases have an unknown etiology, recent considerations point toward genetics as a potential risk factor.<sup>5</sup> Genetic factors contribute to over 5% of affected patients, with monogenetic causes accounting for 5%–10%, although they remain relatively uncommon.<sup>6</sup> In addition to genetic factors, environmental influences such as alcohol consumption, smoking, vitamin D exposure, and urate levels further contribute to the overall risk of PD.<sup>7</sup> PD is characterized by a gradual or persistent loss of dopamine-producing brain cells in the substantia nigra,<sup>8</sup> resulting in a spectrum of motor and non-motor symptoms.<sup>9</sup> Motor symptoms encompass tremor, bradykinesia, akinesia, and postural instability—the final cardinal symptom. Non-motor symptoms extend to sleep disorders, OSAS, olfactory abnormalities, and autonomic nervous system irregularities, including orthostatic hypotension, cardiac arrhythmia, sexual dysfunction, excessive perspiration, and dysfunctional constipation. Behavioral symptoms such as depression, psychosis, and dementia often lead to the neglect of oral health and a decrease in dental appointments.<sup>9,10</sup> Various orofacial manifestations arise from motor symptoms, including temporomandibular dysfunction, tremors in the forehead, eyelids, lip, and tongue musculature, reduced blink rate, chewing problems, and a mask-like face due to a lack of facial expression.<sup>8,11</sup> PD may impact both automatic and voluntary movement,<sup>12</sup> and dysphagia is commonly observed due to pharyngeal motor defects,<sup>8,13,14</sup> often leading to weight loss and a diminished quality of life.<sup>8</sup> Individuals with PD face multiple oral health challenges, including drooling, xerostomia, burning mouth syndrome, poor oral hygiene, and denture-related issues. The poor voluntary and involuntary control of orofacial-pharyngeal muscles exacerbates difficulties such as dysphagia, tremors in the mouth and chin, and challenges in mastication, presenting additional hurdles for oral rehabilitation.<sup>8,15–17</sup> Treatment options for PD patients encompass medication, with levodopa being the most widely used. Anticholinergic medications are also employed; though long-term medication use often leads to partial unresponsiveness in 50–75% of cases.<sup>18</sup> An alternative treatment is deep brain stimulation surgery.<sup>19</sup> However, patients on medication often report experiencing oral health issues like drooling, xerostomia, burning mouth, and poor oral hygiene.<sup>20</sup> Weight loss resulting from these symptoms can further impact the patient's quality of life, particularly in cases involving denture discomfort or mastication issues.<sup>21,22</sup> In addressing the unique challenges posed by PD, effective dental care necessitates a multidisciplinary team.<sup>23</sup> Rehabilitation options range from removable dental prostheses to dental implants, despite a slightly lower success rate in PD patients. The preference for dental implants in planning for dentures signifies a critical advancement in treatment modalities.<sup>10</sup> Comparative analysis reveals the several benefits of mandibular implant overdentures over traditional full mandibular dentures, with increased stability ensuring superior functionality during speech and mastication.<sup>10</sup> Recent case studies highlight the transformative impact of mandibular implant support, underscoring improvements in psychological well-being, speech, and masticatory efficiency—a crucial step towards enhancing overall nutritional status for PD patients. In assessing the impact of implant-supported dentures on Parkinson's patients, evaluating psychological well-being, speech, and masticatory efficiency is crucial. Psychological well-being can be assessed using standardized scales such as the Parkinson's Disease Questionnaire (PDQ-39) or the Geriatric Depression Scale (GDS), which measure mood, quality of life, and depressive symptoms. Speech intelligibility can be evaluated through speech pathology



assessments, including the Frenchay Dysarthria Assessment (FDA) or the Unified Parkinson's Disease Rating Scale (UPDRS). Masticatory efficiency, which is essential for adequate nutrition and overall health, can be objectively measured using tests like the Colorimetric Chewing Gum Test or masticatory performance assessments. Understanding how these parameters are affected and improved by implant-supported dentures in Parkinson's patients contributes to comprehensive care and better treatment outcomes.<sup>24–26</sup> Unfortunately, not all patients, particularly those with PD, can successfully acquire the control necessary for full denture functionality. The advent of Osseo integrated implants has revolutionized missing teeth treatment, offering a groundbreaking solution that significantly reduces challenges associated with traditional dentures.<sup>8,16,17</sup> In conclusion, the evolving landscape of dental care for PD patients emphasizes a comprehensive, multidisciplinary approach. Advancements, ranging from removable dental prostheses to dental implants and the transformative potential of mandibular implant overdentures, are paving the way for an improved quality of life. The development of Osseo integrated implants stands as a testament to the ongoing commitment to overcoming the challenges faced by these individuals, bringing hope and innovation to the realm of dental health in the context of Parkinson's disease.<sup>8,16,17</sup>

**Case Report**

The history of dental implant placement is a tale that spans centuries. Evidence suggests that ancient civilizations like the Mayans and Egyptians experimented with implant-like structures crafted from materials such as ivory and shells to replace missing teeth.<sup>27</sup> However, the foundations of modern implantology were laid in the 20th century. The landmark moment in modern implantology is attributed to Dr. Per-Ingvar Brånemark, a Swedish orthopedic surgeon who, in the 1950s, discovered osseointegration while studying blood flow in rabbit bones.<sup>28</sup> This discovery paved the way for the development of titanium dental implants, capable of integrating with the jawbone, providing a sturdy base for artificial teeth.<sup>29</sup> Initially, dental implants were predominantly placed by oral surgeons or periodontists, specialists in gum diseases.<sup>30</sup> However, as implantology progressed, general dentists also began incorporating implant placement into their practices, sometimes after specialized training.<sup>31</sup> The timing of dental implant placement varies depending on the patient's oral health and treatment plan. In cases where patients require tooth replacement due to conditions like periodontal disease, implants may be considered as an alternative to partial dentures.<sup>32</sup> Whether implants are placed before or after the diagnosis of Parkinson's disease, a neurological disorder, depends on individual patient needs and circumstances.<sup>33,34</sup> A compelling case emerged in our prosthodontics department at Tehran University of Medical Sciences, School of Dentistry, involving an 83-year-old female patient with Parkinson's disease seeking overdenture rehabilitation. The patient presented with a broken mandibular implant-supported overdenture and a worn maxillary complete denture (Figure 1). With a 14-year medical history of Parkinson's disease, the patient was on a medication regimen consisting of Levodopa 100 mg and carbidopa 10 mg. Upon oral examination, distinct clinical features were observed, including soft and monotonous speech, reduced eye blinking, a subtle trembling of the mandible, and limited lip movement during conversation. The intraoral examination revealed reduced salivary flow, well-rounded residual ridges, a deep palatal vault, a type III soft-to-hard palate junction, and two worn Strumann ball abutments on the mandible (Figure 2A and B). Notably, radiographic observation did not reveal any temporomandibular joint (TMJ) pathology (Figure 3A and B). The treatment plan was meticulously crafted, emphasizing the benefits of an implant retention prosthesis



Figure 1 Patient profile.

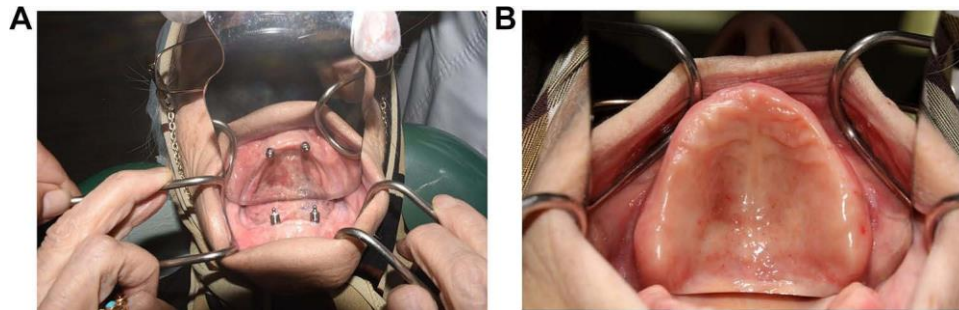


Figure 2 (A and B) - Maxillary Residual Ridges And Mandible With Two Straumann (Rn Standard) Implant.

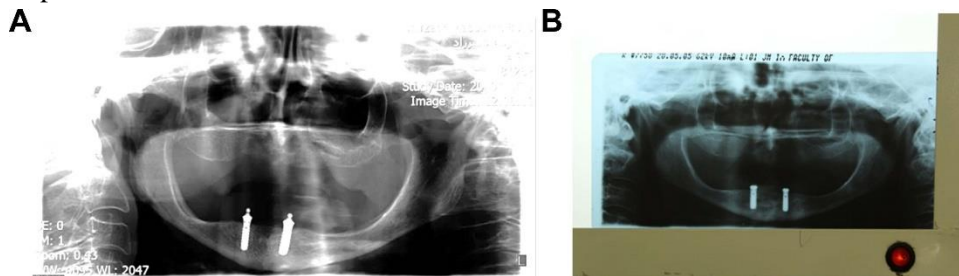
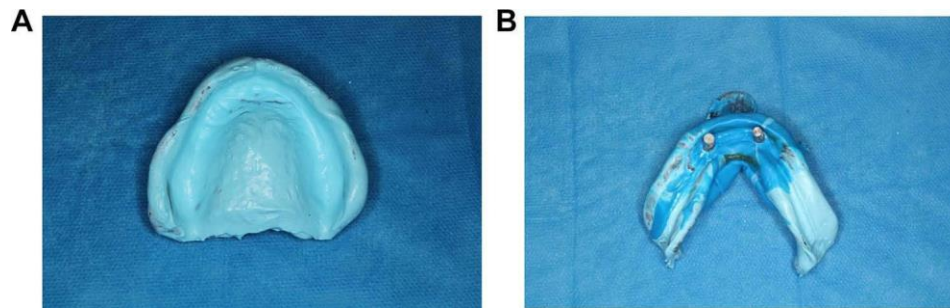


Figure 3 (A and B) - OPG Radiograph (A) After Healing Cap (B) After 17 Year.

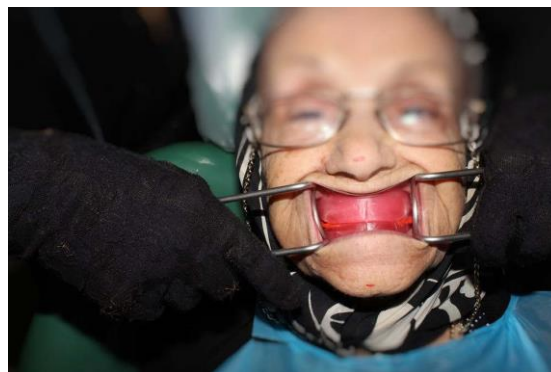
Given the patient's medical condition, specific precautions were taken, including advising the patient to take her Parkinson's disease medication an hour before the visit and ensuring an empty bladder to prevent urinary urgency and incontinence. To foster a compassionate and supportive environment, each 45-minute morning appointment prioritized the patient's comfort and minimized anxiety and frustration. Additionally, a dental chair with a 45-degree tilt was employed to facilitate swallowing. The prosthodontic process

commenced with the creation of a primary impression using irreversible hydrocolloid, followed by a custom tray made from auto-polymerizing acrylic. The selective pressure impression method, incorporating a spacer at the anterior and selective pressure at the posterior, was employed. Implants were splinted with each other after setting impressions. Border molding was accomplished through an incremental process using modeling plastic impression compound, while the final secondary impression utilized zinc oxide and eugenol-free impression material for the maxilla and posterior mandible (Cavex Outline). The anterior portion of the mandible received Panasil Initial Contact Light (KETTENBACH), a light-body polyvinylsiloxane impression material (Figure 4A and B). Before the crucial jaw relation recording, the patient practiced mandibular movement, while Aluwax aided in capturing the sitting occlusion with a slightly lower vertical height than usual (Figure 5).

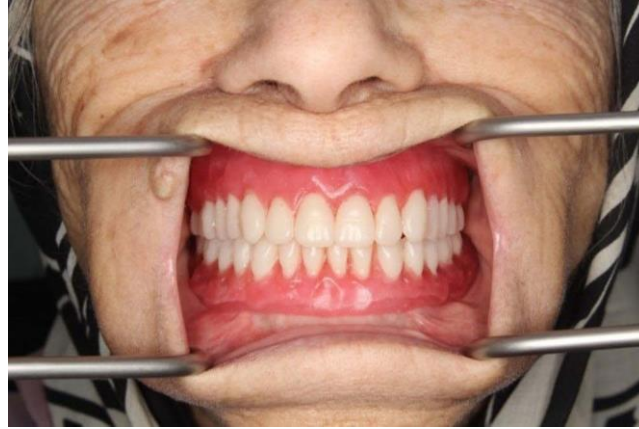**Figure 4 (A and B) - Final Impression Of Maxilla And Mandible.**



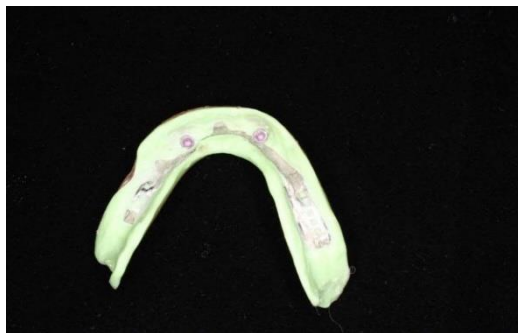The recorded data was transferred to the articulator with the face bowed, and horizontal jaw relation was established through a bilateral manipulation technique. Artificial teeth, aligned with lingualized occlusion in the neutral zone, were positioned, and a trial denture facilitated aesthetic try-in and jaw relation verification. Two subsequent appointments were dedicated to eliminating occlusal interferences (Figure 6). Following the putty index, a GH (Gold Hue) = 0 ball abutment was chosen, and the mandibular overdenture's metal frame was tested with teeth. The final denture was fabricated using high-impact



**Figure 5 Centric Relation And Record Base.**

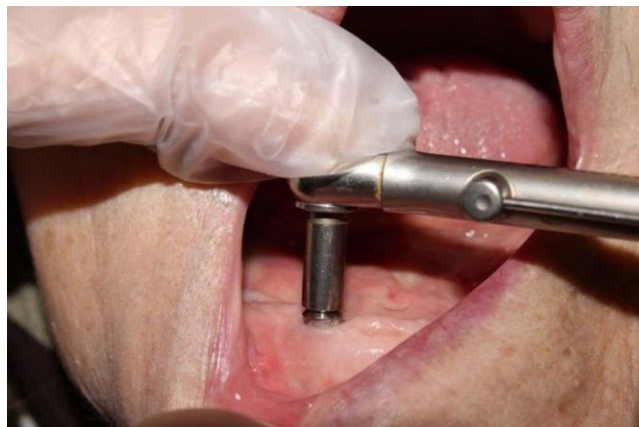

**Figure 6** Teeth Try-In.



**Figure 7** Metal Framework With Base Record Of Mandible.

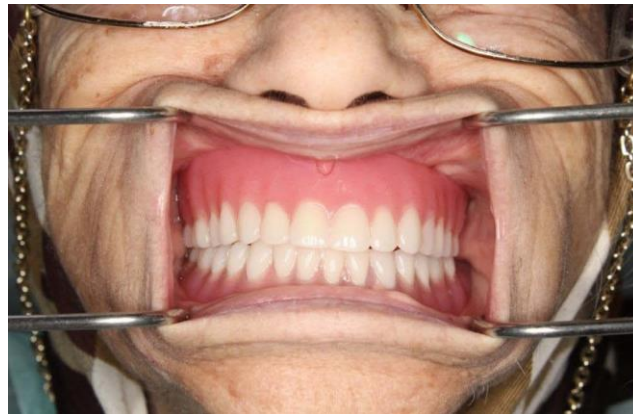denture base resin, with a torque of 20 N applied to the Straumann ball abutment (Figures 7 and 8). Follow-up recall appointments were scheduled to evaluate continuous use and address any potential denture





adjustments (Figure 9). Remarkably, improvements in speech were evident at the first follow-up, occurring 24 hours after delivery, and continued progress was observed at subsequent intervals (3 days, 1 week, 1 month, 3 months, and 6 months). Notably, the patient

**Figure 8** Abutment Tourq.



**Figure 9** Final Over Denture Adjustment.



**Figure 10** Patient Satisfaction.

expressed satisfaction with enhanced chewing ability (Figure 10). This case exemplifies the successful execution of an implant retention prosthesis tailored to the unique challenges posed by Parkinson's disease, highlighting the importance of a comprehensive and patient-centric approach in prosthodontic.



## Discussion

Parkinson's disease, characterized by progressive neurodegeneration, manifests through distinct motor symptoms such as resting tremors, stiffness, and postural instability, alongside unique clinical features like cogwheel-type rigidity and facial impassiveness.<sup>5</sup> As the global elderly population burgeons, geriatric healthcare assumes paramount importance, with dentists playing a pivotal role in enhancing the quality of life for seniors.<sup>35</sup> Patients with Parkinson's disease encounter a spectrum of motor and non-motor complications, adversely impacting their oral health, daily life, and facial expression. The use of medications contributes to oral complications, often leading to premature tooth loss, prompting a need for oral rehabilitation.<sup>36</sup> Implant-supported overdentures, such as OD-1 overdentures, emerge as a viable option, exhibiting superior masticatory efficiency compared to traditional complete dentures. This prosthesis is particularly suitable for patients experiencing issues with traditional mandibular dentures, ensuring enhanced retention without mucosal soreness.<sup>37</sup> Because Parkinson's patients have increased tremors, increased salivation, decreased adaptation skills, and reduced muscle control, creating impressions and recording jaw relationships can be difficult for dentists working with these patients.<sup>36,38</sup> Patients may find it challenging to maintain and retain their dentures due to issues such as a misplaced center of gravity, tongue dislodgment, and stiff facial muscles. The neuromuscular control of oral musculature is pivotal for the success of full dentures, with feedback from temporomandibular joints, musculature receptors, and periodontal ligaments moderating mandibular movement. In the context of compromised feedback in edentulous Parkinson's patients, implant- or tooth-supported overdentures offer advantages in enhanced proprioception and controlled jaw movement.<sup>10</sup> PD patients often face challenges with denture retention and control due to involuntary muscle movements, xerostomia, and rigid musculature. Quick-setting impression material proves beneficial in severe cases, and implant specifications, including divergence, length, width, and bone quality, play crucial roles in the success of overdentures.<sup>39</sup> The choice of self-cleaning abutments and attachment types, such as O-ring designs or ball abutments, further influences plaque control and ease of insertion.<sup>40,41</sup> Lingualized occlusion, chosen for its adjustability and stability during masticatory function, proves to be a pragmatic choice.<sup>42–44</sup> For the majority of Parkinson's patients, a full denture is an imperative component of functional, cosmetic, and psychological rehabilitation. Integrating a comprehensive treatment plan that addresses both physical disabilities and emotional well-being is crucial, requiring a compassionate and understanding approach. The success of treatment outcomes, particularly with two implants and overdentures, hinges on factors like patient motivation, education, and diligent post-treatment follow-up. This holistic approach ensures a tailored response to the multifaceted challenges presented by Parkinson's disease, contributing to the overall well-being of the affected individuals.



Ethical Issue :In our research conducted under Tehran University of Medical Sciences, we acknowledge the paramount importance of upholding ethical standards in medical research. The research protocol for this study is registered with Tehran Medical University’s ethical and research department under #045 ID, meaning that the ID number is related to the study. This raises ethical questions surrounding participant consent. Informed consent from the patient was obtained before we began the study so that the images would be published. Even after getting the participant’s permission and carefully registering with the university’s ethics board, we acknowledge that a comprehensive evaluation of the ethical implications is still necessary. Specifically, our study delves into the participant’s comprehensive understanding and potential repercussions of sharing sensitive information, including personal data and images. We are committed to aligning with ethical guidelines and safeguarding individual privacy throughout the research process. Furthermore, we affirm that all authors actively participated in the study, contributing diverse perspectives. Each image was captured by different team members, and due credit is accorded to the collective efforts of the entire team. Overall, we are dedicated to addressing ethical concerns and ensuring transparency and integrity in our research endeavors.

#### References

1. Tysnes O-B, Storstein A. Epidemiology of Parkinson’s disease. *J Neural transm.* 2017;124(8):901–905. doi:10.1007/s00702-017-1686-y
2. Reichmann H. Clinical criteria for the diagnosis of Parkinson’s disease. *Neurodegener Dis.* 2010;7(5):284–290. doi:10.1159/000314478
3. Alves G, Forsaa EB, Pedersen KF, Gjerstad MD, Larsen JP. Epidemiology of Parkinson’s disease. *J Neurol.* 2008;255(5):18–32. doi:10.1007/s00415-008-5004-3
4. Savica R, Grossardt BR, Bower JH, Ahlskog JE, Rocca WA. Time trends in the incidence of Parkinson disease. *JAMA neurol.* 2016;73(8):981–989. doi:10.1001/jamaneurol.2016.0947
5. Savica R, Cannon-Albright LA, Pulst S. Familial aggregation of Parkinson disease in Utah: a population-based analysis using death certificates. *Neurol Genet.* 2016;2(2). doi:10.1212/NXG.0000000000000065
6. Lill CM. Genetics of Parkinson’s disease. *Molecular and Cellular Probes.* 2016;30(6):386–396. doi:10.1016/j.mcp.2016.11.001
7. Kalia LV, Kalia SK, Lang AE. Disease-modifying strategies for Parkinson’s disease. *Mov Disord.* 2015;30(11):1442–1450. doi:10.1002/mds.26354
8. Friedlander AH, Mahler M, Norman KM, Ettinger RL. Parkinson disease: systemic and orofacial manifestations, medical and dental management. *J Am Dent Assoc.* 2009;140(6):658–669. doi:10.14219/jada.archive.2009.0251
9. Chaudhuri KR, Odin P, Antonini A, Martinez-Martin P. Parkinson’s disease: the non-motor issues. *Parkinsonism Related Disord.* 2011;17 (10):717–723. doi:10.1016/j.parkreldis.2011.02.018
10. Packer M, Nikitin V, Coward T, Davis DM, Fiske J. The potential benefits of dental implants on the oral health quality of life of people with Parkinson’s disease. *Gerodontology.* 2009;26(1):11–18. doi:10.1111/j.1741-2358.2008.00233.x
11. Bakke M, Larsen SL, Lautrup C, Karlsborg M. Orofacial function and oral health in patients with Parkinson’s disease. *European j Oral Sci.* 2011;119(1):27–32. doi:10.1111/j.1600-0722.2010.00802.x
12. Robertson LT, Hammerstad JP. Jaw movement dysfunction related to Parkinson’s disease and partially modified by levodopa. *J Neurol Neurosurg.* 1996;60(1):41–50. doi:10.1136/jnnp.60.1.41
13. Suttrup I, Warnecke T. Dysphagia in Parkinson’s disease. *Dysphagia.* 2016;31(1):24–32. doi:10.1007/s00455-015-9671-9



14. Liu F-C, W-C S, You C-H, AY-J W. All-on-4 concept implantation for mandibular rehabilitation of an edentulous patient with Parkinson disease: a clinical report. *J Prosthetic Dent.* 2015;114(6):745–750. doi:10.1016/j.prosdent.2015.07.007
15. A ZG. Oral motor patterns and their relation to oral prostheses. *J Prosthetic Dent.* 1982;47(5):472–478. doi:10.1016/0022-3913(82)90292-x
16. Rajeswari CL. Prosthodontic considerations in Parkinson's disease. *PJSR.* 2010;3(2):45–47.
17. Katyayan PA, Katyayan MK, Nugala B. Dental management of Parkinson's disease: a case report. *The. New York State Dental j.* 2013;79(5):33–39.
18. Agid Y, Ahlskog E, Albanese A, et al. Levodopa in the treatment of Parkinson's disease: a consensus meeting. *Mov Disord.* 1999;14(6):911–913. doi:10.1002/1531-8257(199911)14:6<911::AID-MDS1001>3.0.CO;2-H
19. Machado A, Rezai AR, Kopell BH, Gross RE, Sharan AD, Benabid AL. Deep brain stimulation for Parkinson's disease: surgical technique and perioperative management. *Mov Disord.* 2006;21(S14):S247–S258. doi:10.1002/mds.20959
20. Zlotnik Y, Balash Y, Korczyn AD, Giladi N, Gurevich T. Disorders of the oral cavity in Parkinson's disease and parkinsonian syndromes. *Parkinson's Dis.* 2015;2015.
21. Ribeiro GR, Campos CH, RCMR G. Parkinson's disease impairs masticatory function. *Clinical Oral Investigations.* 2017;21(4):1149–1156. doi:10.1007/s00784-016-1879-z
22. Rutkauskaitė G, Baltrušaitytė A. Prosthetic dentistry treatment capabilities in Pa-tients with Parkinson's Disease. *Int J Oral Dent Health.* 2020;6:110.
23. Bollero P, Franco R, Cecchetti F, et al. Oral health and implant therapy in Parkinson's patients. *ORAL & Implantology.* 2017;10(2):105. doi:10.11138/orl/2017.10.2.105
24. Müller T, Muhlack S. Depression in Parkinson's disease: the role of age, gender, and disease duration. *Inter Psychogeriatrics.* 2016;28 (11):1901–1910. doi:10.1017/S1041610216001077
25. Logemann JA, Fisher HB, Boshes B, Blonsky ER. Frequency and cooccurrence of vocal tract dysfunctions in the speech of a large sample of Parkinson patients. *J Speech Hear Disord.* 1978;43(1):47–57. doi:10.1044/jshd.4301.47
26. van der Bilt A, Fontijn-Tekamp FA, Bakke M, van der Glas HW. Masticatory function of natural teeth and implants in dental practice. *J Oral Rehabili.* 2004;31(5):461–467. doi:10.1111/j.1365-2842.2004.01287.x
27. Buikstra JE. Dental mutilation and cultural change. *American Anthropeo.* 1974;76(3):560–569.
28. Brånemark PI. Osseointegration and its experimental background. *J Prosthetic Dent.* 1983;50(3):399–410. doi:10.1016/S0022-3913(83)80101-2
29. Brånemark PI, Hansson BO, Adell R, et al. Osseointegrated implants in the treatment of the edentulous jaw. Experience from a 10-year period. *Scandi J Plasti Recons Surg Hand Surg.* 1977;11(Suppl 16):1–132.
30. Lang NP, Berglundh T. Periimplant diseases: where are we now?—Consensus of the Seventh European Workshop on Periodontology. *J Clinic Period.* 2011;38(S11):178–181. doi:10.1111/j.1600-051X.2010.01674.x
31. Misch CE, Bidez MW. A scientific rationale for dental implant design. In: *Contemporary Implant Dentistry.* 3rd ed. Mosby; 2008:319–330.
32. Wilson Jr. TG Jr. The positive relationship between excess cement and peri-implant disease: a prospective clinical endoscopic study. *Journal of Periodontology.* 2009;80(9):1388–1392. doi:10.1902/jop.2009.090115
33. Zarb GA, Albrektsson T. Osseointegration: a requiem for the periodontal ligament? *Int J Periodon Restorative Dentistry.* 1991;11(2):88–91.



34. Ribeiro GR, Campos CH, RCMR G. Influence of a removable prosthesis on oral health-related quality of life and mastication in elders with Parkinson disease. *J Prosthetic Dent.* 2017;118(5):637–642. doi:10.1016/j.prosdent.2016.12.018
35. Srivanitchapoom P, Pandey S, Hallett M. Drooling in Parkinson's disease: a review. *Parkinsons Relate Disord.* 2014;20(11):1109–1118. doi:10.1016/j.parkreldis.2014.08.013
36. Singh Y, Saini M, Garg N. Oral rehabilitation of a Parkinson's patient: a case report. *World Journal of Clinical Cases: WJCC.* 2013;1(1):67. doi:10.12998/wjcc.v1.i1.67
37. Khalid T, Yunus N, Ibrahim N, Saleh NBM, Goode D, Masood M. Assessment of masticatory function of mandibular implant-supported overdenture wearers: a 3-year prospective study. *J Prosthetic Dent.* 2020;124(6):674–681. doi:10.1016/j.prosdent.2019.08.005
38. Kieser J, Jones G, Borlase G, MacFadyen E. Dental treatment of patients with neurodegenerative disease. *N Z Dent J.* 1999;95(422):130–134.
39. Heckmann SM, Schrott A, Graef F, Wichmann MG, Weber HP. Mandibular two-implant telescopic overdentures. *Clin Oral Implants Res.* 2004;15(5):560–569. doi:10.1111/j.1600-0501.2004.01064.x
40. Ajay Mootha M, Jaiswal SS, Dugal R. Prosthodontic Treatment in Parkinson's Disease Patients: Literature Review. *Journa.* 2018;46(11):691.
41. ELSyad MA, Errabti HM, Mustafa AZ. Mandibular denture base deformation with Locator and ball attachments of implant-retained overdentures. *J Prosthodontics.* 2016;25(8):656–664. doi:10.1111/jopr.12356
42. Engelmeier RL, Phoenix RD. The development of lingualized occlusion. *J Prosthodontics.* 2019;28(1):e118–e31. doi:10.1111/jopr.12624
43. Phoenix RD, Engelmeier RL. Lingualized occlusion revisited. *J Prosthetic Dent.* 2010;104(5):342–346. doi:10.1016/S0022-3913(10)60153-9
44. Olanow CW, Stern MB, Sethi K. The scientific and clinical basis for the treatment of Parkinson disease. *Neurology.* 2009;72(21 Supplement 4):S1–S136. doi:10.1212/WNL.0b013e3181a1d44chabilitation

